



Your local Radiology practice with 25 years of service to the Penrith Community

NEWSLETTER – Summer 2006

Derby Street

Suite 4 Gnd Flr, 68 Derby Street PENRITH

Phone: 4737 3300

Monday - Friday 8am - 6pm

Saturday 8.30am - 12.30pm

No General X rays on Saturdays

Castlereagh Street

16-18 Castlereagh Street PENRITH

Phone: 4731 6977

Monday - Friday 8am - 5pm

Saturday 8.30am - 12.30pm

Range of Services

Plain X-rays

OPG

Ultrasound: Abdomen, Pelvis, Obstetric, Breast,
Thyroid, Vascular, Musculoskeletal

CT scanning - 16 slice

Mammography, Ductography

Fluoroscopy - Barium Swallow/Meal/Enema. Small bowel studies,

MCU, HSG, Sialogram, Myelogram, Joint and Capsule Injection

MRI - Brain, Spine, Musculoskeletal

Biopsies - Breast, Thyroid, Chest, Abdomen, Musculoskeletal

Radiologists:

Dr Stephen Cahill, Dr Anthony Leung, Dr Michael Reeves, Dr Julie Schatz and Dr Greg Markson

are responsible for the practice and the quality of service we provide.

Chief Radiographer: Simon Bird

Deputy Chief Radiographer: Barbara Hoar

Operations Manager: Nicole Szmelter

Team Leaders:

Derby Street: Nicole Carroll (Centre Service Corinator)

Castlereagh Street: Karen Sapwell

CASE STUDY

CT Pelvis: Vesico-Colonic Fistula

Dr Anthony Leung

Dr Stephen Cahill

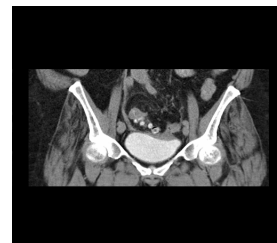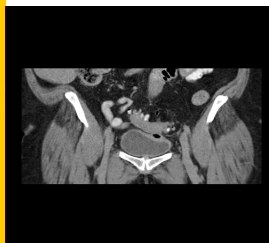
66 years old female presented with pneumoturia and known history of diverticulitis.

The sigmoid colon is adjacent to the top of the bladder with an air filled diverticulum in contact with the bladder wall.

There is some thickening of the top of the bladder wall suggesting inflammation .

The sagittal reformatted images in supine and prone positions show small amount of air within the bladder with an air-fluid level. Note: Layering of contrast within the bladder.

Colovesical fistula is the most common type of fistulous communication between the urinary bladder and the bowel. Diverticular disease is the most common cause (cancer much less likely). CT scan is the most sensitive test for detecting a colovesical fistula, showing small amounts of air or contrast in the bladder, thickening of the bladder wall, or a gas-containing adjacent mass. Barium enema rarely reveals a fistula but may confirm diverticular disease and help exclude cancer.



Christmas Hours

23rd Dec—Saturday	Closed
Christmas Day	Closed
Boxing Day	Closed
27th Dec—29th Dec	8am—4pm
30th Dec—Saturday	Closed
New Years Day	Closed

From the Radiologists and Staff of Penrith Imaging, we would all like to wish each and every one of you a very Merry Christmas and a Happy and Safe New Year.

Thank you, for all your support and assistance during 2006.

We all look forward to working with you in 2007.

Nicole Szmelter
Operations Manager